



JeffEcker
HAND & WRIST SURGEON

JE: SK
August 31, 2023

Dr Latha KUMAR
Kenwick Medical Centre
119 Kenwick Road
KENWICK WA 6107

Dear Latha

RE: **Sohee KIM (DOB: 05/06/98)**
398 High Rd
RIVERTON WA 6148

Thank you for referring Sohee he can who is a 25-year-old right-hand-dominant chef at the crown's Casino.

Problem: Left wrist pain

Diagnosis: Left de Quervain's tenosynovitis with a separate sub-compartment for the extensor pollicis brevis. This is clearly demonstrated on ultrasound and MRI

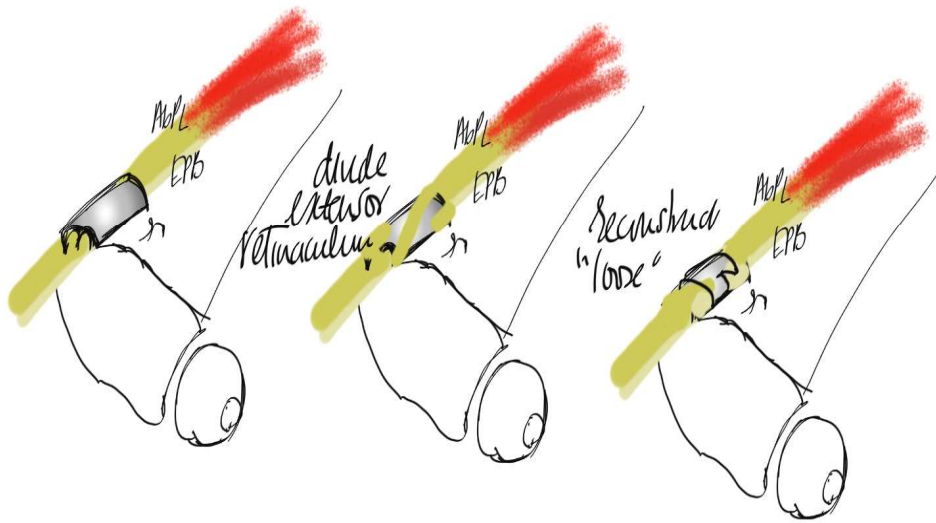
History: Onset of left radial wrist symptoms in January 2023. A steroid injection has not been effective in resolving her symptoms.

Recommended management

1. *Surgical release of the first extensor compartment with particular reference to the sub-compartment for the extensor pollicis brevis and retinacular rotation flaps* to prevent secondary iatrogenic instability of the abductor pollicis longus and extensor pollicis brevis tendons.

2. Sohee will be in a splint for 3 weeks and will then have an exercise program to rehabilitate the wrist.

Work impact: Could return to full-time restricted jobs if she does not have to use the left wrist, get it wet or dirty or be in contact with food with her left hand and wrist within a week of operation. It will be at least 3-4 weeks or slightly longer before she will be able to return to full unrestricted work as a chef.



Yours sincerely

Dictated, but not sighted by

JEFF ECKER

047805DL

cc. Miss Sohee KIM
398 High Rd
RIVERTON WA 6148

Please note: This letter has been checked for typographical errors & grammar only, not clinical content.